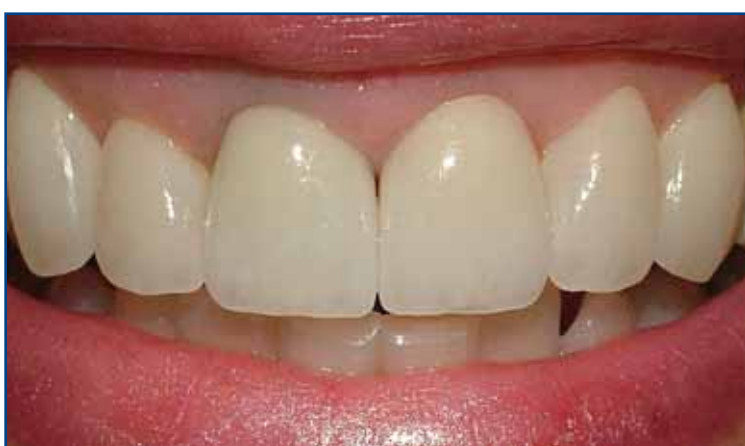
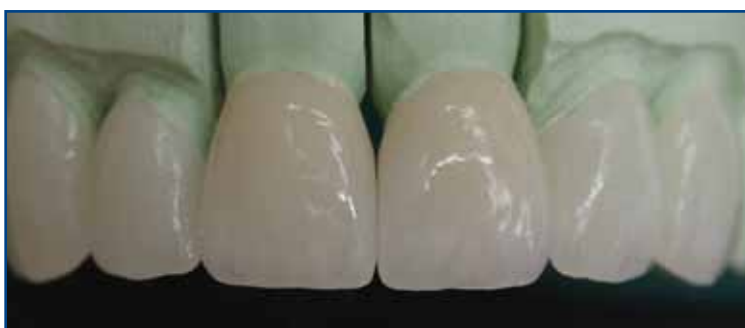
SOLUTIONS **2**

VOLUME **2**

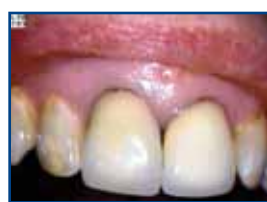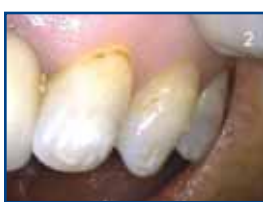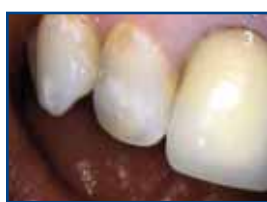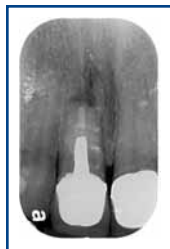ANTERIOR COMBINATION CASE OF LAVA™ CROWNS AND VIBRANT™ VENEERS



Clinical work: Dr. Mark Ceroni
Lab work: Rotsaert Dental Laboratory

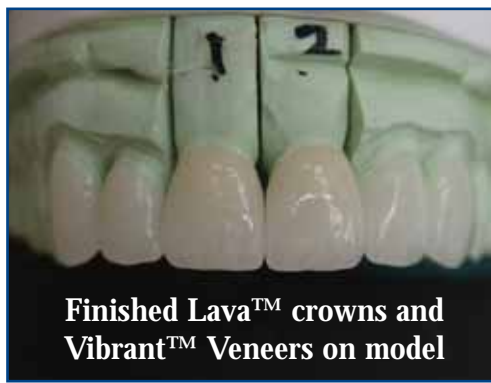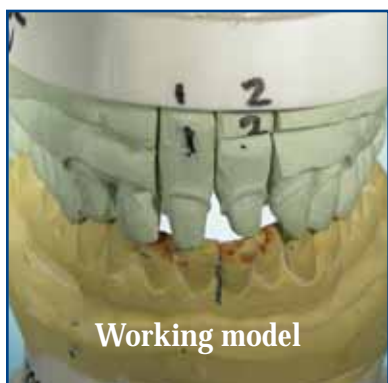
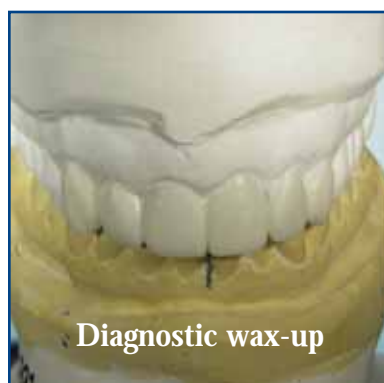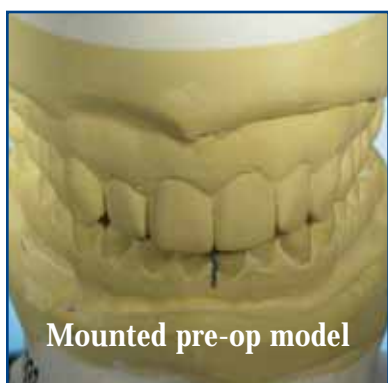
PROBLEM:

Patient has old PFM's on the centrals. Tetracycline staining of laterals and cuspids. Patient wants to revitalize the smile, making it brighter and more appealing



SOLUTION:

3M™ ESPE™ LAVA™ Zirconia crowns were chosen for the two centrals because of the warmth of the aesthetics and since we're dealing with old crowns, the underlying colour of the preps will be masked by the unique attributes of the material. Vibrant™ Feldspathic veneers were also chosen because of the minimal preparation required.



SEQUENCE:

For ideal results the lab creates a diagnostic wax up, working within the parameters of function and existing periodontal situation. For this specific case the centric contacts and canine rise were not altered. Temps are fabricated from duplicating the wax-up in the mouth. Function, phonetics, tooth shape and size are worked out on the temps. After preparation appointment, have patient come back to check and address any concerns. Take photos of temps and describe any issue that might have arisen and communicate to the lab.